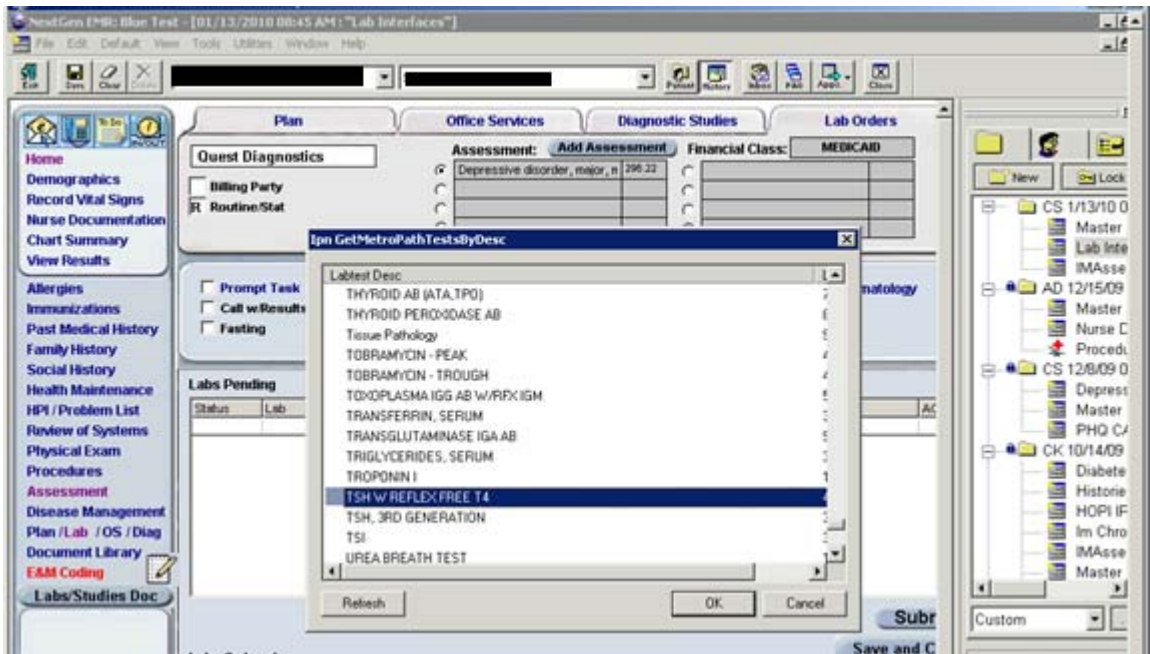


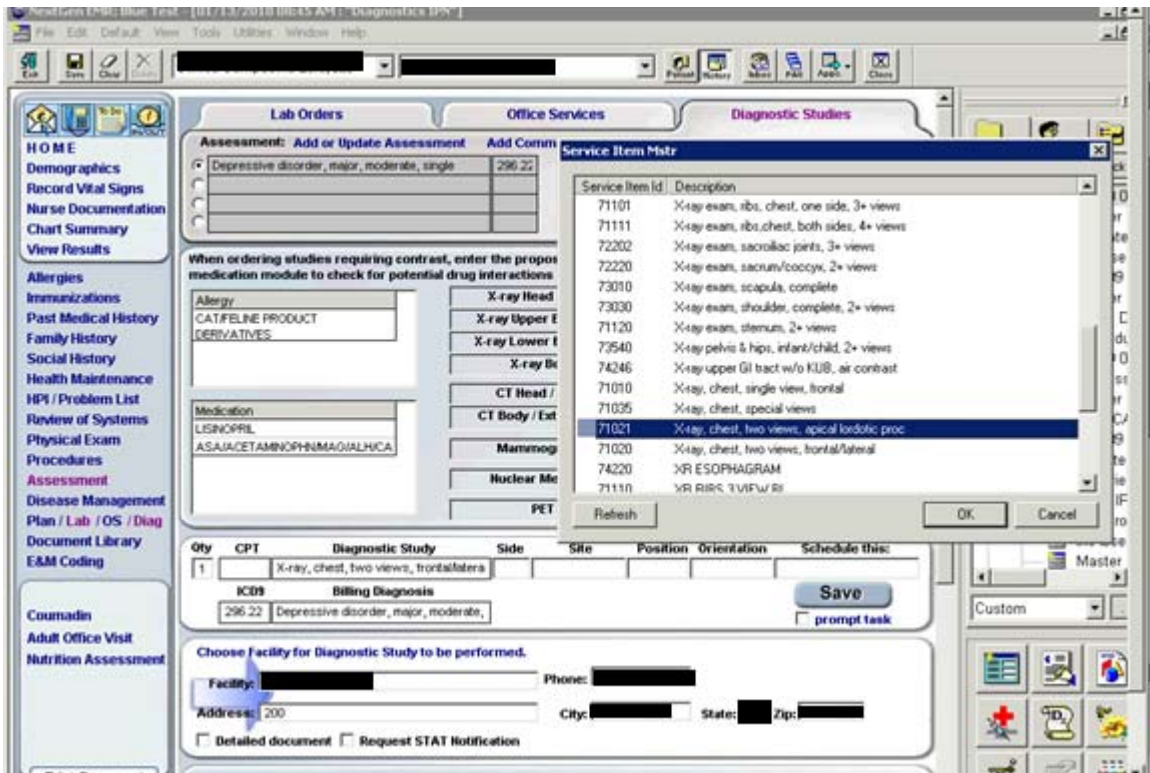
PPC 6: TEST TRACKING

Element B: Electronic System for Managing Tests

Item 1: Order lab tests



Item 2: Order imaging tests



Date Of Request: 01/13/2010

PATIENT
 Name: Blue Test Phone: [REDACTED]
 Address: [REDACTED] Date of Birth: 07/19/1948

INSURANCE
 Name: Medicaid FGHC Phone: [REDACTED]
 Address: [REDACTED]
 Group #: [REDACTED] Policy #: Y654734

DIAGNOSTIC FACILITY
 Name: [REDACTED] Phone: [REDACTED]
 Address: [REDACTED]

TYPE OF STUDY(ies) REQUESTED

CPT	Order	Site	Site	Position	Comments
71021	X-ray, chest, two views, apical lordotic proc				

ICD-9 Diagnosis
 296.22 Depressive disorder, major, moderate, single
 [REDACTED]
 [REDACTED]

Item 3: Retrieve lab results directly from source

We have a full point to point interfaces with Quest, Lab Corp, Unipath, Centura and Metropath

Collection Date & Time	12/17/2009	11/19/2009	05/07/2009	03/06/2009	11/14/2008	10/03/2008	04/11/2008	03/19/2008
CBC (INC. DIFF/PLT)	16.02	15.43	15.23	09.50	16.22	15.42	15.53	10.08
ABSOLUTE BASOPHILS		23	27	29	77			
ABSOLUTE EOSINOPHILS		86	116	130	143			
ABSOLUTE LYMPHOCYTES		1148	1278	1113	1076			
ABSOLUTE MONOCYTES		423	503	391	398			
ABSOLUTE NEUTROPHILS		2822	4876	2537	3407			
BASOPHILS		0.5	0.4	0.2	1.5			
EOSINOPHILS		1.9	1.7	3.1	2.8			
HEMATOCRIT		36.2	37.3	35.8	37.5			
HEMOGLOBIN		12.5	12.7	12.4	13.0			
LYMPHOCYTES		25.5	18.8	26.5	21.1			
MCH		31.8	31.4	31.2	31.5			
MCHC		34.6	34.1	34.7	34.8			
MCV		91.8	92.0	89.8	90.6			
MONOCYTES		9.4	7.4	9.3	7.8			
MPV		9.4	9.1	8.6	10.4			
NEUTROPHILS		62.7	71.7	60.4	66.8			
PLATELET COUNT		215	211	235	164			
RBC		3.94	4.06	3.99	4.14			
RDW		12.8	12.4	13.0	13.4			
WBC		4.5	6.8	4.2	5.1			

CULTURE, URINE
 CULTURE, URINE FINAL

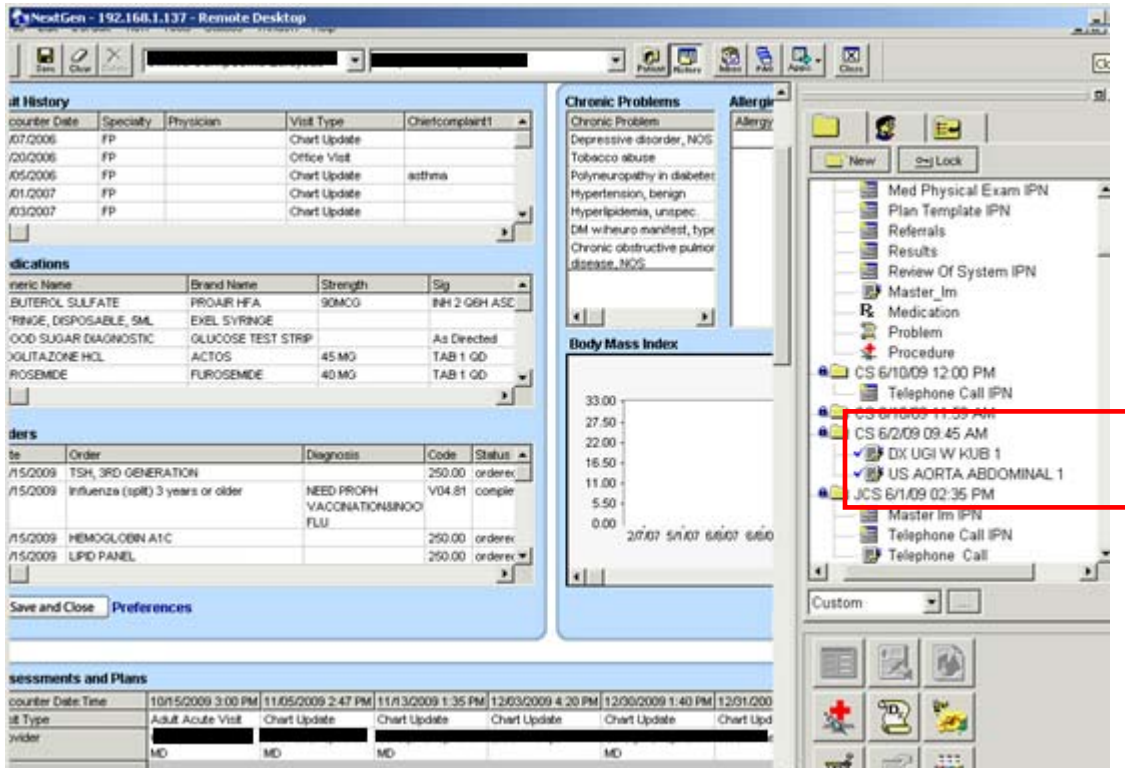
Value: FINAL Units: Range: Flag:

History: Result Comments: SINGLE ORGANISM LESS THAN 10,000 CFU/mL ISOLATED. THESE ORGANISMS, COMMONLY FOUND ON EXTERNAL AND INTERNAL GENITALIA, ARE CONSIDERED COLONIZERS. NO FURTHER TESTING PERFORMED.

Lab
 LabCorp
 Unipath
 Centura
 Quest Diagnostics
 Metropath

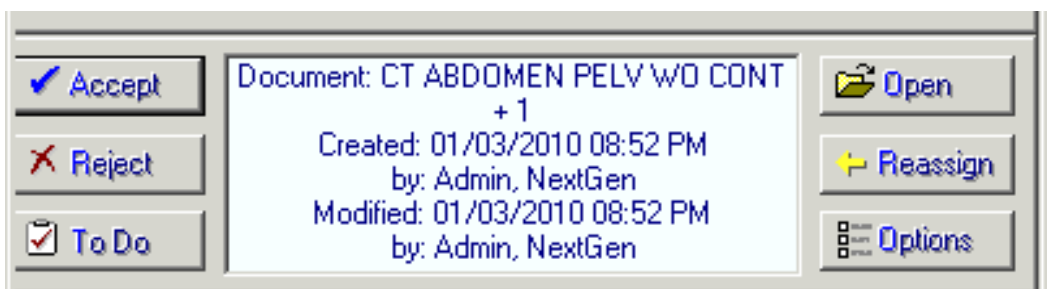
Item 4: Retrieve imaging text reports directly from source

Through Mobile MD the reports and dictations are interfaced into the patient’s EHR. The blue checkmark indicates that the document was “signed off” through the Provider Approval Queue.



Item 6: Route and manage current and historical test results to appropriate Clinical personnel for review, filtering and comparison

The provider approval queue (PAQ) directs labs, images, notes, documents and data from HIE to the primary care provider. These then need to be “Accepted” which is the same as signed off, they can be reassigned to other providers or they can be rejected altogether, sent back to our Medical records department if the patient is not our patient. The To Do button allows sending a task (such as to a nurse for follow up) right from the PAQ and attaches the document or lab for easy retrieval.



PAQ for lab result, flagged as high.

Signoff Queue

Pending Rejected History

Description	Date-Time
Lab: High	M 01/05/2010 12:29 AM
CT ABDOMEN PEL	M 01/03/2010 08:52 PM

Preview Comments

Panel Name: PTROTHROMBIN TIME
Status: F
Comments:

Result Name: INR
Value: 4.5
Range: SEE COMMENTS
Flags: H
Units: RATIO
Comments: INR: REFERENCE RANGE 0.9-1.1
MODERATE-INTENSITY WARFARIN THERAPY 2.0-3.0
HIGHER-INTENSITY WARFARIN THERAPY 3.0-4.0

Result Name: PROTINE PATIENT
Value: 42.8
Range: 9.0-11.5
Flags: H
Units: SECONDS
Comments: Report Comment
EOI-[1265-NGP663196-5071-6932***C-1262624559]
[REDACTED] H.D., MEDICAL DIRECTOR.

Accept Reject To Do

Lab: High
Created: 01/05/2010 09:33 PM
by [REDACTED]
Modified: 01/05/2010 12:29 AM
by Admin, NextGen

Open Reassign Options

Font... Add

PAQ with Imaging document from Xxxx Hospital.

Signoff Queue

Pending Rejected History

Description	Date-Time
Lab: High	M 01/05/2010 12:29 AM
CT ABDOMEN PEL	M 01/03/2010 08:52 PM

Preview Comments

REPORT #1 12270007 ORDER #1 12270190

ATTENDING:
PCP: [REDACTED]
ORDERING: [REDACTED]

EXAM: CT ABDOMEN PELV WD CONT + DATE OF EXAM: 12/27/09 13

Signed

CT ABDOMEN AND PELVIS WITHOUT CONTRAST
12/27/2009

CLINICAL HISTORY: Right lower quadrant pain. History of stones.

TECHNIQUE: Noncontrast axial CT acquisitions through the abdomen/pelvis with coronal reconstructions.

FINDINGS: The visualized lung bases and cardiomeastinum within limits.

Unenhanced limited evaluation of the liver, spleen, pancreas, adrenal glands and left kidney is unremarkable.

Page 1/1 Line 46 Col 1

Accept Reject To Do

Document: CT ABDOMEN PELV WD CONT *1
Created: 01/03/2010 08:52 PM
by Admin, NextGen
Modified: 01/03/2010 08:52 PM
by Admin, NextGen

Open Reassign Options

Font... Add